MDCAT BY FUTURE DOCTORS (TOUSEEF AHMAD)

UNIT

16

SUPPORT AND MOVEMENT

KEY CONCEPTS

16.1 Human skeleton
16.2 Disorders of skeleton
16.3 Muscles

MDCAT BY FUTURE DOCTORS (TOUSEEF AHMAD)

Some support in living organisms is necessary to uphold and sustain the body against gravity and other external forces. As the living organisms increased in size through the process of evolution, the need for support became greater. This was particularly true once living organisms left water and colonized land. The skeleton in animals contributes to this support.

16.1 HUMAN SKELETON

The vertebrate skeleton is composed either of cartilage or bone. Both tissues provide an internal supporting framework of the body. Human adults have bony skeleton, but cartilage is also present in some regions.

16.1.1 Cartilage:

Cartilage is a type of connective tissue consisting of cells called chondrocytes and a tough, flexible matrix made of type II collagen. Unlike other connective tissues, cartilage does not contain blood vessels and the chondrocytes are supplied by diffusion. Because of this, it heals very slowly.

Although the human skeleton is initially made up of cartilages and fibrous membranes, most of these early supports are soon replaced by bones. A few cartilages that remain in adults are found mainly in regions where flexible skeletal support is needed. There are three types of cartilage tissue in human body: hyaline, elastic, and fibrocartilage.

16.1.2 Bone

Bone is a rigid form of connective tissue, which forms the endoskeleton of vertebrates. Bone is a living hard (resists compression) and strong (resists bending) structure. It consists of a hard ground substance or matrix and cells. In the adult human, the matrix consists of about 65% inorganic matter (calcium phosphate, carbonate etc) and about 35% organic substances (protein, collagen). The cells are embedded in the matrix.

The structure of bone is specially designed to withstand the compression strains falling upon it and to resist pressure. Bones are composed of cells for example; **osteoblasts** (cells that help **form** bone), and **osteoclasts** (cells that help **eat away** old bone).

Fig: 16.1 Different types of bone cells.

MDCAT BY FUTURE DOCTORS (TOUSEEF AHMAD)

In addition, bone contains cells called **osteocytes**, which are mature osteoblasts that have ended their bone-forming capacity. These cells engage in metabolic exchange with the blood that flows through the bones.

Osteoblasts:

The osteoblasts are mononucleate cells. Osteoblasts produce a matrix which is composed mainly of Type I collagen. They are also responsible for mineralization of this matrix. Osteoblasts are the immature bone cells, and eventually become entrapped in the bone matrix to become osteocytes- the mature bone cell.

Osteocytes:

They are mature bone cells. They cease to generate mineralized matrix. Osteocytes have many extensions that reach out to meet osteoblasts and other osteocytes for the purposes of communication. They are responsible for the maintenance of bone and calcium . They also regulate the bone's response to stress and mechanical load.

Osteoclast:

Osteoclasts are large, multinucleated cells that remove bone tissue by removing its mineralized matrix and breaking up the organic bone. This process is known as bone resorption. They are equipped with phagocytic-like mechanisms similar to circulating macrophages.

Composition of Bone

Bone is a dynamic tissue that is being reshaped by the activity of osteoclasts and osteoblasts. Cells are embedded in a firm calcified matrix. 30% matrix is composed of organic material, chiefly of collagen fibers (90%) and glycoproteins. 70% matrix is composed of inorganic salts. The chief inorganic constituent of bone is needle like crystals of hydroxyapatite, a form of calcium phosphate. Sodium, magnesium, potassium, chloride, fluoride, bicarbonate and citrate ions are also

Table: 16.1 Comparison between bone and cartilage

BONE	CARTILAGE
(i) Mature cells are osteocytes.	(i) Mature cells are chondrocytes
(ii) Bone matrix contains type I collagen.	(ii) Cartilages mostly contain type II collagen
(iii) Strengthen by inorganic calcium salts.	(iii) No inorganic salts
(iv) Bones are constantly reshaped by osteoblasts, and osteoclasts.	(iv) Cartilages are not reshaped
(v) Bones have rich blood supply.	(v) No blood circulation in cartilages

MDCAT BY FUTURE DOCTORS (TOUSEEF AHMAD)

present in variable amounts. Calcium and phosphate may be released into the blood as needed, under the control of two hormones, **parathormone** and **calcitonin**.

16.1.3 Main divisions of human skeleton

A skeleton of cartilage supports human body, but by the time of birth much of the cartilage had been transformed into 350 bones. As one grows many of these bones fuse with one another so that at adult stage, skeleton consists of 206 individual bones which are grouped into two general divisions; axial skeleton, the basic framework of the body and appendicular skeleton, the extremities. Axial skeleton consists of skull, vertebrae and ribs. Appendicular skeleton includes pectoral girdle with forelimbs and pelvic girdle with hind limbs. Numbers and distribution of bones in human body is given in the table 16.2.

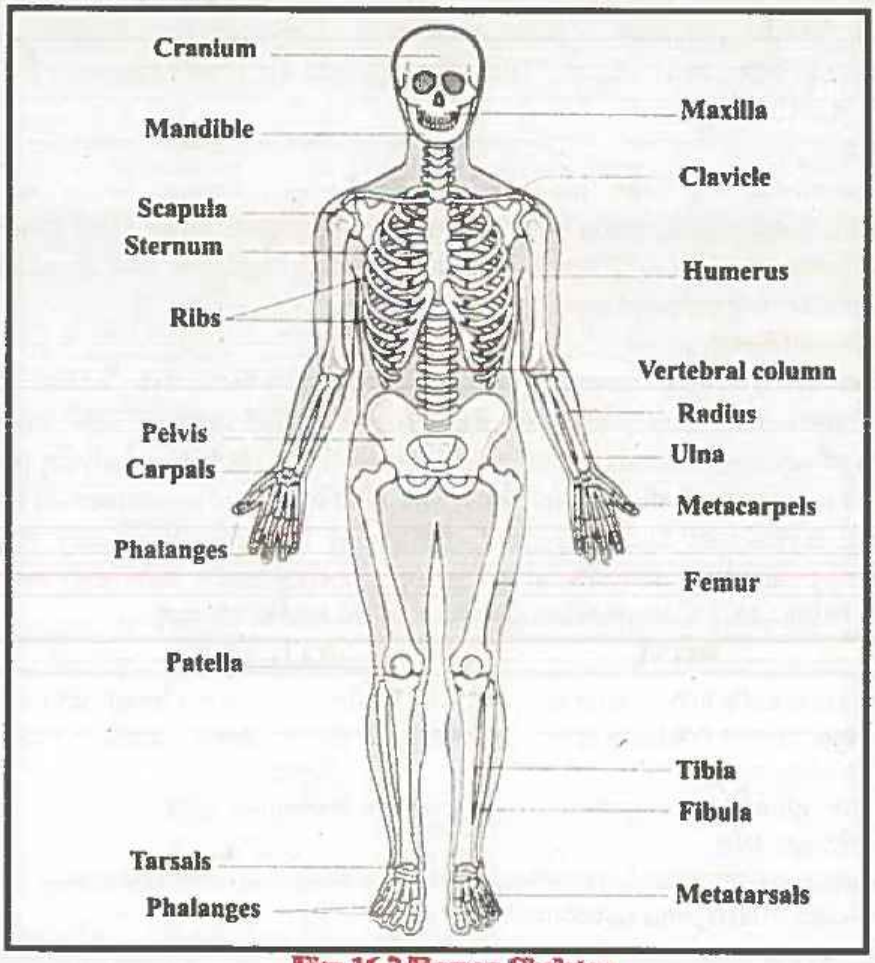

Fig: 16.2 Human Skeleton

MDCAT BY FUTURE DOCTORS (TOUSEEF AHMAD)

Table: 16.2 Distribution of bones in human body.

Main part	*Subdivision*		*Total bones*
Skull	Cranium Ears Face	8 bones 6 bones 14 bones	28
Neck Trunk	Hyoid Vertebral column Chest bone Ribs	bone 1 26 bones 1 24 bones	1 51
Limbs	Upper limbs Lower limb	64 62	126

Table: 16.3 The 28 bones of the skull are tabulated here.

Skull	*Unpaired bones*	*Paired bones*
Cranium 8 bones	Frontal Occipital Sphenoid Ethmoid	Parietal Temporal
Facial bones (face) 14 bones	Mandible Vomer	Maxilla Zygomatic Lacrimal Nasal Inferior concha Palatine
Auditory ossicle (ear bones) 6 bones		Malleus Incus Stapes

MDCAT BY FUTURE DOCTORS (TOUSEEF AHMAD)

Axial Skeleton

Axial skeleton consists of skull, vertebral column and ribs.

1. ***Skull*** The skull consists of cranium (or facial bones), ear bone (or auditory ossicles) and hyoid bone. The primary function of skull is the protection of brain. The human skull is composed of 22 bones, besides 6 tiny ear bones and one hyoid bone.

At the time of birth several of the bones of the cranium are not completely formed. If the bones of cranium were completely formed at the time of birth, great difficultly would have been experienced in the birth canal.

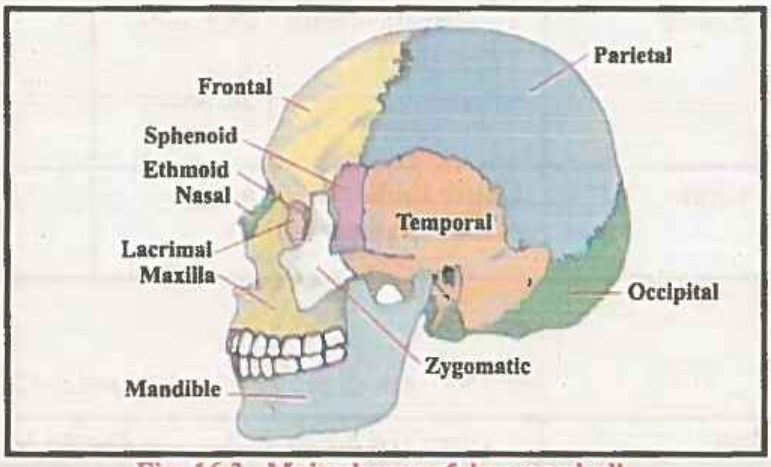

Fig: 16.3 Major bones of human skull.

2. ***Vertebral Column***

The vertebral column forms a more or less rigid rod. It extends through the length of the trunk on the dorsal side and form the backbone. It houses and protects the spinal cord. It is a place of attachment of pelvic and pectoral girdle.

In man, there are 33 vertebrae. Seven cervical vertebrae in the neck region; in the thorax region 12 thoracic vertebrae; in the lower back region 5 lumber vertebrae; in the sacral region 5 sacral vertebrae (to which the pelvic girdle is attached) and at the end of the vertebral column is the coccyx or tail bone which consists of 4 small fused vertebrae. The coccyx is man's vestige of a tail.

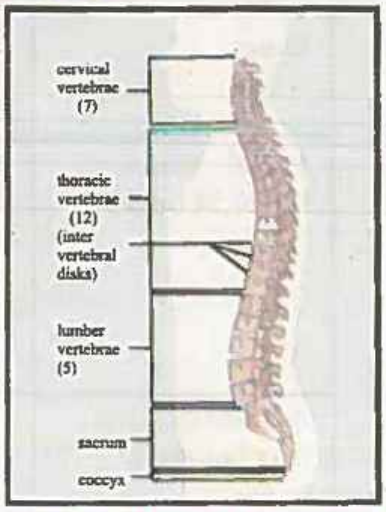

Fig: 16.4 Vertebral column of the human skeleton (side view)

MDCAT BY FUTURE DOCTORS (TOUSEEF AHMAD)

3. *Ribs*

In man there are twelve pairs of ribs, one pair articulating with each of the thoracic vertebrae forming a cage that encloses the heart and lungs. Ten pairs of ribs are connected anteriorly with the sternum. Seven pairs out of these ten pairs are directly connected with the sternum and are known as 'true ribs, while the other three pairs are indirectly connected with the sternum through costal arch and are known as 'false ribs'. The lower two pairs of ribs are not attached in front and are known as the "floating ribs".

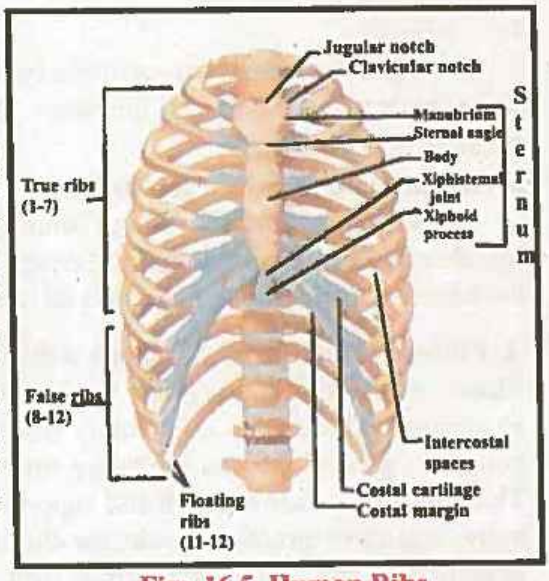

Fig: 16.5 Human Ribs

Appendicular Skeleton

The appendicular skeleton consists of pectoral girdles with forelimbs and pelvic girdle with hind limbs.

Pectoral Girdle

The bones of the pectoral girdle consists of a ventral coracoid, which meets the sternum medially; a scapula, extending dorsally; and a clavicle, which lies on the ventral side between the scapula and sternum and anterior to the coracoid.

Forelimbs

The forelimbs consist of a humerus in the upper arm region; a radius and an ulna in the lower arm region; 8 carpels in the wrist and 5 metacarpels in the palm of the hand and 14 phalanges.

Pelvic Girdle

Hind limbs are attached to the vertebral column through pelvic girdle, which is made of two coxal bones. Each of these bones are found by the combination of three bones; ischium, illium and pubis.

Hind limbs

Each hind limb consists of thigh, shank, ankle and foot. In the hind limb there is a single femur in the thigh, a pair of bones, the tibia and fibula, in the shank, 8 anklebones, followed by five longer metatarsals in the foot and finally five rows of fourteen phalanges in the toe.

MDCAT BY FUTURE DOCTORS (TOUSEEF AHMAD)

16.1.4 Joints

The sites where two or more bones meet are called joints or articulations. Joints have two fundamental functions: they give mobility to the skeleton and hold the skeletal parts together.

Structural classification of joints

Structural classification of joints is based on the material binding the bones together and whether or not a joint cavity is present. There are three types of joints, the fibrous, cartilaginous, and synovial joints.

1. Fibrous joints: In fibrous joints, a thin layer of fibrous connective tissue holds the bones firmly in position. There is no joint cavity between the bones. In general fibrous joints are immovable. These joints provide strength and support for the body, and have protective role for the delicate structures. Fibrous joints are formed between the bones of skull, between sacrum and iliac of pelvic girdles, and between the bones of pelvic girdle.

Fig: 16.6 Fibrous joints in skull.

ii. Cartilaginous joints: Cartilaginous joints are connected entirely by fibrocartilage or hyaline cartilage. Joint cavity is absent. Bones can glide over each other to a limited extent. Cartilage forms a flexible connection so that these joints allow slight movement. Such joints are formed between vertebrae, and between wrist and ankle bones.

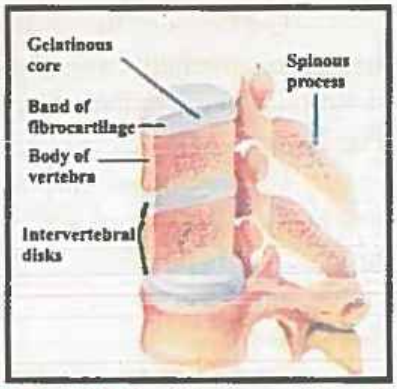

Fig: 16.7 Cartilaginous joints in vertebral column.

Synovial joints: Synovial joints are those in which the articulating bones are separated by a fluid-containing joint cavity (synovial cavity). This arrangement permits freedom of movement, and all synovial joints are freely movable.

Synovial joints are reinforced and strengthened by a number of bandlike **ligaments**. These ligaments hold the bones in position. Based on the shape of their articular surfaces, the synovial joints have different structural plan. This structural plan determines the type of movement allowed.

MDCAT BY FUTURE DOCTORS (TOUSEEF AHMAD)

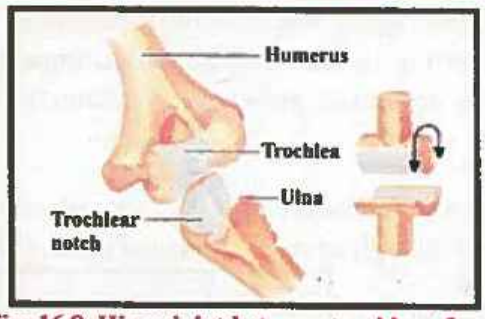

Fig: 16.8 Hinge joint between trochlea of humerus and trochlear notch of ulna at the elbow.

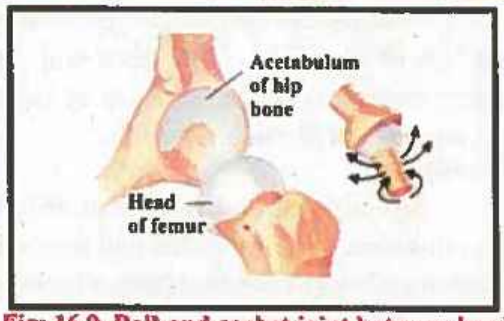

Fig: 16.9 Ball-and-socket joint between head of the femur and acetabulum of the hip bone.

The synovial joints can be classified into two major categories; hinge and ball and socket joints.

Hinge joints: In hinge joints, a cylindrical projection of one bone fits into a trough-shaped surface on another. These joints permit movement in one plane that is, permit flexion and extension only. Hinge joints are capable of bearing heavy loads. Examples are elbow and knee joint.

Ball-and-Socket Joints: In ball-and-socket joints the spherical or hemispherical head of one bone articulates with the cuplike socket of another. These joints are the most freely moving synovial joints. The shoulder and hip joints are examples.

16.2 DISORDERS OF SKELETON

16.2.1 Disorders of human skeleton:

Although human skeleton is hard and strong, yet deformities do occur resulting in reduced movement or complete immovability. Deformities of skeleton may be genetic, hormonal or due to the effects of nutrient deficiency

Disc slip:

The discs are protective shock-absorbing pads between the bones of the spine (vertebrae). The discs of the spine are also referred to as intervertebral discs. Although they do not actually "slip," a disc may split or rupture. This can cause the disc cartilage and nearby tissue to fail (herniate), allowing the inner gel portion of the disc to escape into the surrounding tissue. This leaking jelly-like substance can place pressure on the spinal cord or on an adjacent nerve to cause symptoms of pain either around the damaged disc or anywhere along the area controlled by that nerve. This condition is also known as a herniated disc. The most frequently affected area is in the lower back, but any disk can rupture, including those in the neck.

MDCAT BY FUTURE DOCTORS (TOUSEEF AHMAD)

Factors that lead to a slipped disc include aging with associated degeneration and loss of elasticity of the discs and supporting structures; injury from improper lifting, especially if accompanied by twisting or turning; and excessive strain forces associated with physical activities.

Spondylosis:

Spondylosis (spinal osteoarthritis) is a degenerative disorder that may cause loss of normal spinal structure and function. Although aging is the primary cause, the location and rate of degeneration is individual.

The degenerative process of spondylosis may affect the cervical (neck), thoracic (mid-back), or lumbar (lower back) regions of the spine.

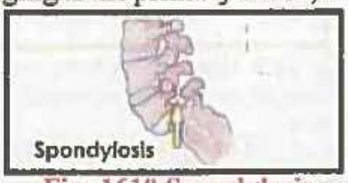

Fig: 1610 Spondylosis.

Sciatica:

Sciatica refers to pain, weakness, numbness, or tingling in the leg. It is caused by injury to or pressure on the sciatic nerve. This nerve starts in the lower spine and runs down the back of each leg. Common causes of sciatica include: Slipped disc, piriformis syndrome (a pain disorder involving the narrow muscle in the buttocks), pelvic injury or fracture and tumors.

Arthritis:

The arthritis is joint inflammation and it can affect joints in any part of the body. Arthritis is the leading cause of disability in those over the age of 65. Some of the symptoms of arthritis are:

- Joint pain and swelling.
- Stiffness particularly in the mornings.
- The feeling of warmth around a joint.
- Redness of skin around the joint.
- Inability to move the joint easily.

Some of the causes of arthritis are broken bone, infection in the area, an autoimmune disease and general wear and tear on joints.

16.2.2 Bone fractures

A fracture is the medical term for a broken bone. They occur when the physical force exerted on the bone is stronger than the bone itself. So bones break when they cannot withstand a force or trauma applied to them.

- **Simple fracture: Closed (simple) fractures** are those in which the skin is intact.

MDCAT BY FUTURE DOCTORS (TOUSEEF AHMAD)

- **Compound fracture:** The fracture is an open (compound) fracture if the bone ends penetrate the skin and form a wound.

Repair of a fractured bone:

A fracture is treated by reduction, the realignment of the broken bone ends. In closed or external reduction, the bone ends are coaxed into position by the physician's hands. In open (internal) reduction, the bone ends are secured together surgically with pins or wires. After the broken bone is reduced, it is immobilized by a cast to allow the healing process to begin. For a simple fracture the healing time is six to eight weeks for small or medium-sized bones in young adults, but it is much longer for large, weight-bearing bones and for bones of elderly people (because of their poorer circulation). Repair in a simple fracture involves four major stages;

- **Hematoma formation:** When a bone breaks, blood vessels in the bone, and perhaps in surrounding tissues, are torn and hemorrhage occur. As a result, a hematoma, a mass of clotted blood, forms at the fracture site. Soon, bone cells deprived of nutrition die, and the tissue at the site becomes swollen, painful, and inflamed.
- **Fibrocartilaginous callus formation:** Within a few days, several events lead to the formation of soft granulation tissue, also called the soft callus. Capillaries grow into the hematoma and phagocytic cells invade the area and begin cleaning up the debris. Meanwhile, fibroblasts and osteoblasts invade the fracture site and begin reconstructing the bone.

The fibroblasts produce collagen fibers that span the break and connect the broken bone ends, and some differentiate into chondroblasts that secrete cartilage matrix.

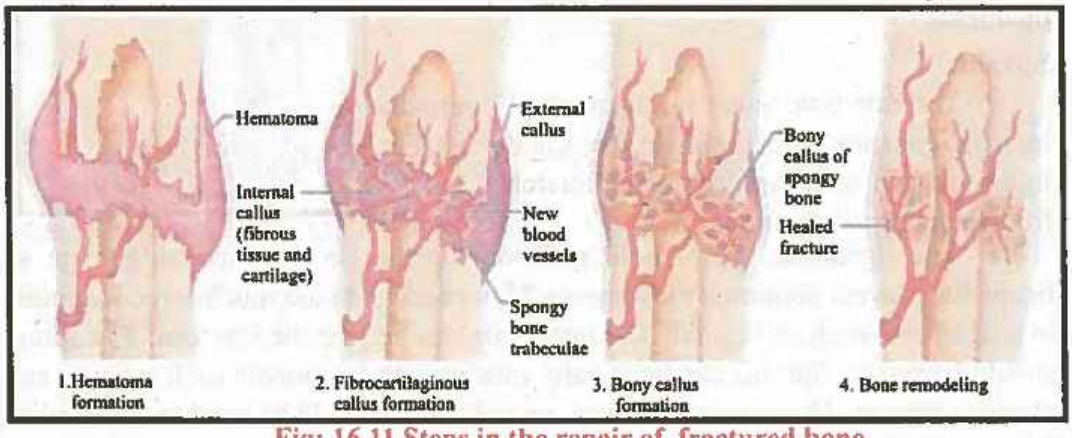

Fig: 16.11 Steps in the repair of fractured bone.

MDCAT BY FUTURE DOCTORS (TOUSEEF AHMAD)

Within this mass of repair tissue, osteoblasts begin forming spongy bone, but those farthest from the capillary supply secrete an externally bulging cartilaginous matrix that later calcifies. This entire mass of repair tissue, now called the fibrocartilaginous callus, splints the broken bone.

- **Bony callus formation:** Within a week the fibrocartilaginous callus is gradually converted to a bony (hard) callus of spongy bone. Bony callus formation continues until a firm union is formed about two months later.
- **Bone remodeling:** Beginning during bony callus formation and continuing for several months after, the bony callus is remodeled. The compact bone is laid down to reconstruct the shaft walls. The final structure of the remodeled area resembles that of the original unbroken bony region because it responds to the same set of mechanical stressors.

16.2.3 Joint injuries:

Joint dislocation:

A dislocated joint is a joint that slips out of place. It occurs when the ends of bones are forced away from their normal positions. When a joint is dislocated, it no longer functions properly. A severe dislocation can cause tearing of the muscles, ligaments and tendons that support the joint. Symptoms include; swelling, intense Pain, and immobility of the affected joint. The most common causes are a blow, fall, or other trauma to the joint. In some cases, dislocations are caused by a disease or a defective ligament.

Rheumatoid arthritis can also cause joint dislocation. A dislocated joint usually can only be successfully 'reduced' into its normal position by a trained medical professional. Surgery may be needed to repair or tighten stretched ligaments.

Sprain:

A sprain is an injury to a ligament. Commonly injured ligaments are in the ankle, knee, and wrist. The ligaments can be injured by being stretched too far from their normal position.

Fig: 16.12 Ligaments in the ankle.

The ligaments are to hold skeleton together in a normal alignment so ligaments prevent abnormal movements. However, when too much force is applied to a ligament, such as in a fall, the ligaments can be stretched or torn. The sprain should be rested. Sprains can be usually treated with treatments such as icing and physical therapy. Dressings, bandages, or ace-wraps should be used to immobilize the sprain and provide support.

MDCAT BY FUTURE DOCTORS (TOUSEEF AHMAD)

16.3 MUSCLES

Muscle is a specialized tissue of mesodermal origin. Muscle tissue makes up nearly half the human body mass. The most distinguishing functional characteristic of muscles is their ability to transform chemical energy (ATP) into mechanical energy. In doing so, they become capable of exerting force.

16.3.1 Types of muscles

Based on their location, three types of muscles are skeletal, cardiac, and smooth.

i. Skeletal Muscles

Skeletal muscles are attached to and cover the bony skeleton. Skeletal muscle fibers are multinucleated, the longest muscle cells having obvious stripes called striations and are under voluntary control. They can contract rapidly, but get tire easily and must rest after short periods of activity, or fatigued. Nevertheless, it can exert tremendous power.

Skeletal muscles are also remarkably adaptable. For example, hand muscles can exert a force of a fraction of an ounce to pick up a dropped paper clip and the same muscles can exert a force of many pounds to pick heavy loads like a bucket full of water. Skeletal muscles are primarily involved in locomotory actions and changes of body postures.

Fig: 16.13 Structure of skeletal muscle.

ii. Cardiac Muscles

Cardiac muscles occur only in the heart where they constitute the bulk of the heart walls. Cardiac muscle cells are arranged in a characteristic branching pattern. Like skeletal muscle cells, cardiac muscle cells are striated, but are involuntary and have single nucleus.

Cardiac muscles usually contract at a fairly steady rate set by the heart's pacemaker, but neural controls allow the heart to "shift into high gear" for brief

MDCAT BY FUTURE DOCTORS (TOUSEEF AHMAD)

periods.

Rhythmic contraction of cardiac muscles in atria and ventricles of the heart pump blood throughout the body.

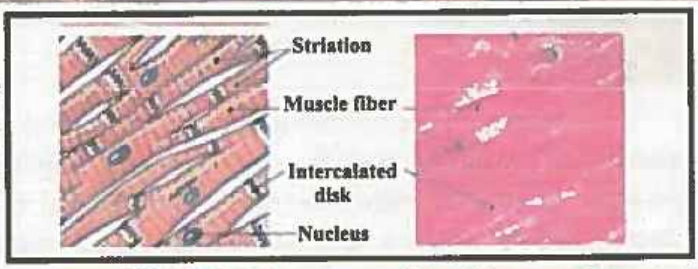

Fig: 16.14 Structure of cardiac muscle

iii. Smooth Muscles

Smooth muscles are found in the walls of hollow visceral organs, such as the stomach, urinary bladder, respiratory passages, and blood vessels. Smooth muscle cells are spindle shaped. They have one centrally placed nucleus per cell. They have no striations, and are not subjected to voluntary control.

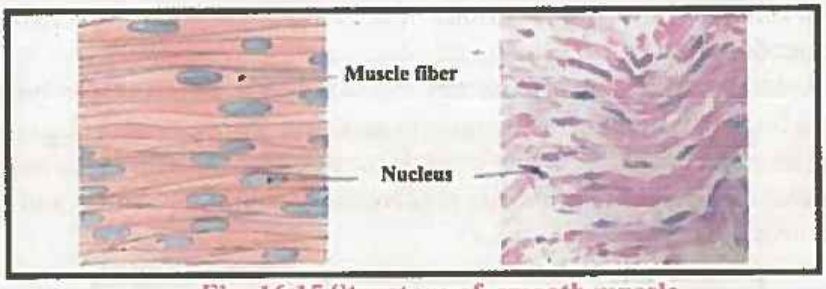

Fig: 16.15 Structure of smooth muscle.

16.3.2 Structure of Skeletal Muscles

The skeletal muscles are attached to the skeleton. The skeletal muscle consists of muscles bundle, which are further composed of huge elongated cells called muscles fibre. These muscles fibres are cylindrical, unbranched and with a diameter of 10–100μm.

Each fibre consists of a semi fluid matrix, the sarcoplasm or cytoplasm, containing many nuclei and a large number of mitochondria. The nuclei are located near the periphery of each fibre.

Each fibre is surrounded by a membrane sarcolemma. The sarcolemma of muscle fibre cell penetrates deep into the cell to form hollow elongated tube, the transverse tubule, T-tubule. The lumen of which is continuous with the extracellular fluid. The T-tubule and terminal portion of the adjacent envelope of sarcoplasmic reticulum (a modified type of endoplasmic reticulum that store calcium) form triads at regular intervals along the length of the fibril.

MDCAT BY FUTURE DOCTORS (TOUSEEF AHMAD)

The nerve impulse is carried through the T-tubule to the adjacent sarcoplasmic reticulum. Fibre may be red, due to the presence of the myoglobin- an oxygen storing pigmented protein. It also contain large amount of stored glycogen.

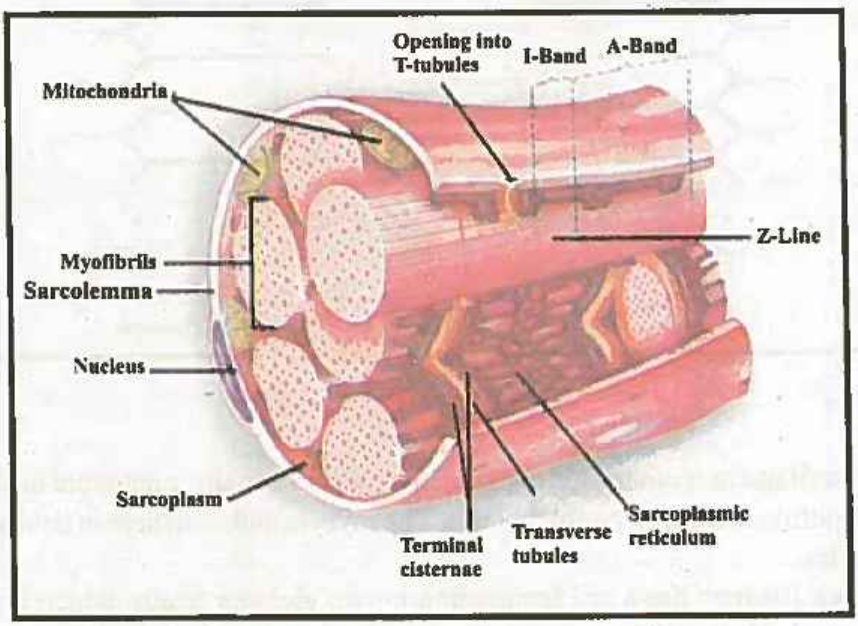

Fig: 16.16 Section through a muscle fibre.

The sarcoplasm of the fibre contains many contractile elements called myofibrils, which are 1 –2μm in diameter. Each myofibril has alternate light and dark bands, which give the fibre its "striped" appearances. It is because of this, that the skeletal muscles are also called striated or striped muscles.

Myofibrils consist of smaller contractile units called sarcomere. In each sarcomere a series of dark and light bands are evident along the length of each myofibril. The dark bands are A band (anisotropic) and the light band are I band (isotropic). Each A band has a lighter strip in its midsection called H-zone (hele for bright) which inturn is bisected by M –line (medial line). The I band have midline called Z –line (zwish meaning between). A sarcomere is the region of a myofibril between two successive Z –line. The region of myofibril is the sarcomere, which is the functional unit of the contraction process in the muscles.

Each myofilament is made up of central thick filament surrounded by thin filament, which are linked together by cross bridges. The thick filament contains a protein, myosin.

MDCAT BY FUTURE DOCTORS (TOUSEEF AHMAD)

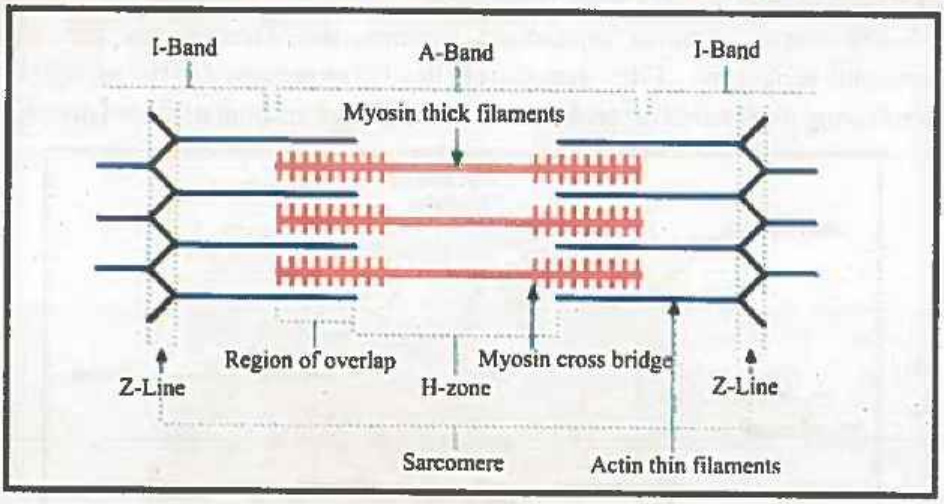

Fig: 16.17 Composition of sarcomere.

Thin filament is composed of a protein actin as its main component besides it also has tropomyosin and troponin proteins. The myosin and actin help in contraction of the muscles.

Thick filament has a tail terminating in two globular heads, which are also called as cross bridges and these link thin and thick filaments during contraction.

Muscles Contraction

Contractility or the ability to contract is a fundamental characteristic of living substance. It is essential to all kinds of movements, except growth and cytoplasmic streaming.

The currently popular model of muscle fiber contraction is called the **sliding filament hypothesis** proposed by H .E. Huxely and A. F. Huxely. They observed that when the muscle contracts, the thick and thin filaments of the muscles fibre slide past each other but are not changed in length.

According to this model, the release of calcium ions from the sarcoplasmic reticulum causes a reorientation of certain components in the thin actin filaments, permitting them to bind with extensions (heads) from the thick myosin filaments.

Each myosin head then binds and splits an ATP molecule and the energy released powers the head forward to the next binding component on the actin filament.

MDCAT BY FUTURE DOCTORS (TOUSEEF AHMAD)

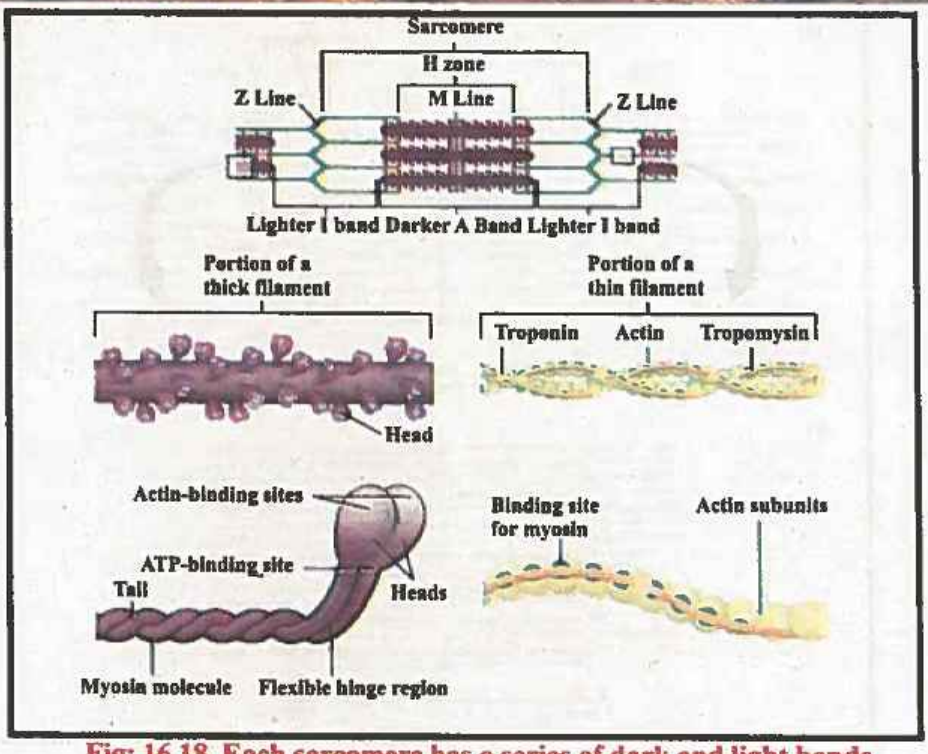

Fig: 16.18 Each sarcomere has a series of dark and light bands which are evident along the length of each myofibril.

As this occurs, the actin filament moves one "notch" past the myosin filament. As long as calcium ions and ATP are available in the cytoplasm, the myosin heads continue to "crawl" along the actin filaments, thereby contracting the sarcomere and muscle.

Recovery: Muscle Fibre Relaxation

When the electrical impulses reaching a muscle fibre cease, the sarcoplasmic reticulum begins to re-accumulate the calcium ions by active transport. Once most of the calcium is sequestered in the sarcoplasmic reticulum sacs, which takes only milliseconds, the binding between the myosin heads and the actin filaments can no longer occur. As a result, the thick and thin filaments slide past one another, returning to their relaxed state of minimal overlap. The sarcomeres (and muscle fibres) once again achieve their maximal length and stretchability.

Control of Muscle Contraction

The contraction of a muscle fibre is normally an all-or- none phenomenon. Once it is stimulated, a muscle fibre will contract to a set length, regardless of intensity of the stimulus above the threshold level.

MDCAT BY FUTURE DOCTORS (TOUSEEF AHMAD)

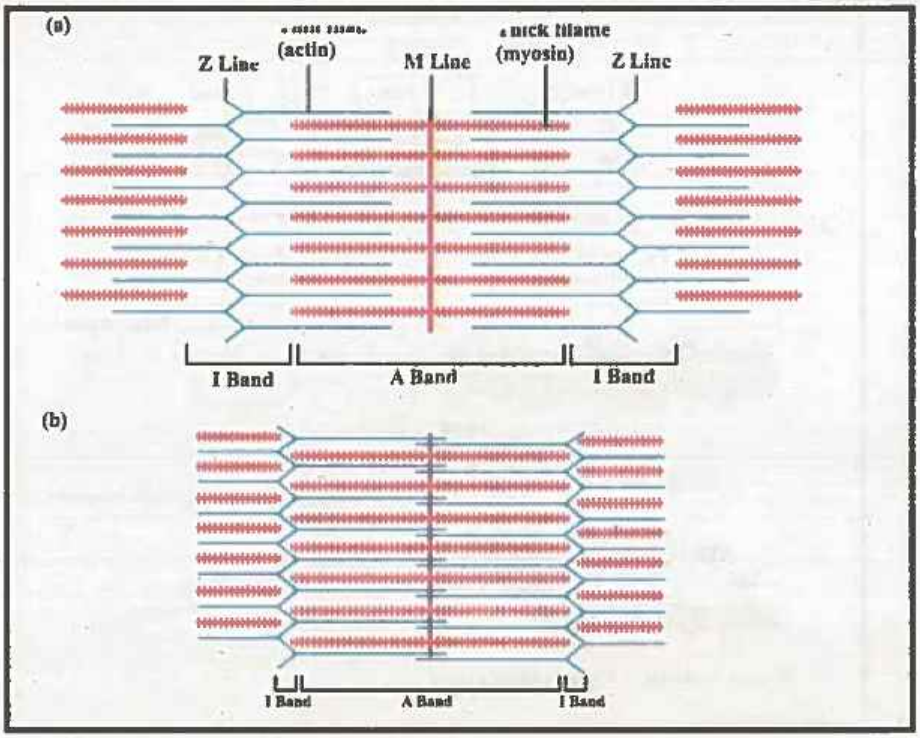

Fig: 16.19 Sarcomere exhibiting contraction movement.

The question then arises: If fibre contraction is an all-or- none phenomenon, how do we manage the fine control of muscular activity that permits us to lift a pencil on one occasion and a bowling ball on another?

Part of the answer has to do with the physical relationship between motor neurons and muscle fibres. The axon of a motor neuron has many branches, each branch terminating at a single muscle fibre. Thus, depending on how many branches it has, one neuron can stimulate several to many different muscle fibres. All the muscle fibres triggered by a single neuron contract simultaneously as a single **motor unit.** Since a particular muscle may consist of many motor units, the total amount of muscle contraction depends on the number of motor neurons conducting impulses to their motor units in that muscle. If many neurons carry impulses at once, many motor units within the muscle will contract. This causes a stronger over all contraction of the muscle than if only a few motor units are activated.

MDCAT BY FUTURE DOCTORS (TOUSEEF AHMAD)

Energy of Muscle Contraction

Muscle contraction needs energy. The immediate source of energy for the muscle contraction is ATP, stored in the muscle cells. An enzyme ATPase, in the muscle cells breaks ATP to ADP, thus releasing energy for muscle contraction. But much part of the energy comes from carbohydrates or glucose, stored as glycogen in the muscle cells. When muscle contraction begins, glycogen is converted into glucose, which is then broken down to form ATP. The muscle contraction then uses this ATP.

We know that in violent exercise, such as running, much energy is needed. Is the normal rate of formation of ATP in muscles fibers adequate for this? Apparently not, but the muscles cells of all vertebrates have a reserve of high-energy phosphate compound, called phosphocreatin. During periods of intensive muscular activity, the phosphocreatin is broken into creatin and a high-energy phosphate group. This group then unites with ADP to form ATP.

Of the total energy expended in muscles contraction, only about35% is utilized for the performance of work; the remaining is liberated in the form of heat, which is employed to maintain body temperature. In cold weather the production of heat can be increased through voluntary muscular activity (walking, rubbing hand together etc) or involuntary by shivering. Conversely, in warm weather, muscular activity is deliberately decreased to reduce heat production.

16.3.5 Muscle problems

I. Cramps: Muscle cramps are sudden, involuntary contractions or spasms in one or more muscles. They often occur after exercise or at night, lasting a few seconds to several minutes. Writer's cramp is a familiar example of temporary contractures. Muscle cramps can be caused by nerves that malfunction. Other causes are, straining or overusing a muscle, dehydration, lack of minerals in diet or the depletion of minerals in body, and not enough blood getting to muscles.

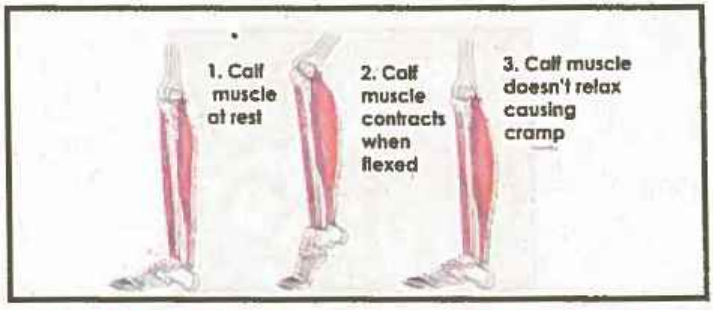

Fig: 16.20 Cramps are involuntary contractions or spasms in one or more muscles.

MDCAT BY FUTURE DOCTORS (TOUSEEF AHMAD)

ii. Muscle fatigue:

Muscle fatigue is a condition of the muscle in which its capacity to produce maximum contraction is reduced even though the muscle still may be receiving stimuli. Availability of ATP declines during contraction and a total lack of ATP results in contractures, states of continuous contraction because the cross bridges are unable to detach. Although excessive intracellular accumulation of lactic acid (which causes the muscles to ache and raises H^+) alters contractile proteins, other ionic imbalances also contribute to muscle fatigue. In general, intense exercise of short duration produces fatigue rapidly via ionic disturbances, but recovery is also rapid. In contrast to short-duration exercise, the slow-developing fatigue of prolonged low-intensity exercise may require several hours for complete recovery.

iii. Tetany:

Tetany is a symptom characterized by muscle cramps, spasms or tremors. These repetitive actions of the muscles happen when muscle contracts uncontrollably. Tetany may occur in any muscle of the body, such as those in face, fingers or calves. The muscle cramping associated with tetany can be long lasting and painful. A common cause of tetany is very low levels of calcium in the body.

Tetanus:

Tetanus is infection of the nervous system with the potentially deadly bacteria *Clostridium tetani*. Spores of the bacteria *C. tetani* live in the soil and are found around the world. In the spore form, *C. tetani* may remain inactive in the soil, but it can remain infectious for more than 40 years. Infection begins when the spores enter the body through an injury or wound. The spores release bacteria that spread and make a poison called tetanospasmin. This poison blocks nerve signals from the spinal cord to the muscles, causing severe muscle spasms. The spasms can be so powerful that they tear the muscles or cause fractures of the spine.

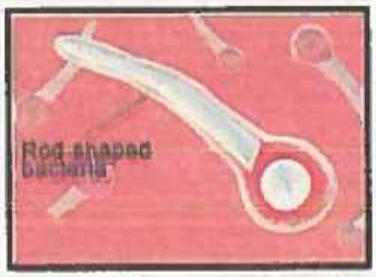

Fig: 16.21 ***Clostridium tetani***

MDCAT BY FUTURE DOCTORS (TOUSEEF AHMAD)

KEY POINTS

- The skeleton in animals contributes in upholding and sustaining the body against gravity and other external forces.
- The vertebrate skeleton is composed either of cartilage or bone.
- **Cartilage consists of cells called chondrocytes and a tough, flexible matrix made of type II collagen and it is without** blood vessels.
- Bone is a living hard and strong structure consisting of a hard ground substance or matrix and cells.
- Bones are composed of **osteoblasts** (cells that help **form** bone), and **osteoclasts** (cells that help **eat away** old bone) and **osteocytes** which are mature osteoblasts.
- Human skeleton consists of 206 individual bones which are grouped into two general divisions; axial skeleton, the basic framework of the body and appendicular skeleton, the extremities.
- The human skull is composed of 22 bones, besides 6 tiny ear bones and one hyoid bone.
- In human, there are 33 vertebrae. Seven cervical vertebrae, 12 thoracic vertebrae; 5 lumber vertebrae; 5 sacral vertebrae and at the end of the vertebral column is the coccyx or tail bone which consists of 4 small fused vertebrae.
- In human there are twelve pairs of ribs, one pair articulating with each of the thoracic vertebrae forming a cage that encloses the heart and lungs.
- The appendicular skeleton consists of pectoral girdles with forelimbs and pelvic girdle with hind limbs.
- The sites where two or more bones meet are called joints or articulations.
- Deformities of skeleton may be genetic, hormonal or due to the effects of nutrient deficiency.
- A fracture means broken bone.
- **Simple fractures** are those in which the skin is intact.
- Compound fracture is an open fracture: if the bone ends penetrate the skin and form a wound.
- A dislocated joint is a joint that slips out of place.
- Based on location, three types of muscles are skeletal, cardiac, and smooth.
- The skeletal muscle consists of muscles bundle, which are further composed of huge elongated cells called muscles fibre..

MDCAT BY FUTURE DOCTORS (TOUSEEF AHMAD)

KEY POINTS

- The immediate source of energy for the muscle contraction is ATP, stored in the muscle cells. An enzyme ATPase, in the muscle cells breaks ATP to ADP, thus releasing energy for muscle contraction.
- Muscle fatigue is a condition of the muscle in which its capacity to produce maximum contraction is reduced even though the muscle still may be receiving stimuli.
- Muscle cramps are sudden, involuntary contractions or spasms in one or more muscles.
- Tetany is a symptom characterized by muscle cramps, spasms or tremors.
- Tetanus is a infection of the nervous system caused by a deadly bacteria *Clostridium tetani.*

MDCAT BY FUTURE DOCTORS (TOUSEEF AHMAD)

EXERCISE ?

1- Multiple Choice Questions

(i) ***The disorder in which bones are porous and thin but bone composition is normal is;***

(a) osteomalacia (b) osteoporosis
(c) rickets (d) arthritis

(ii) ***The organic portion of bone's matrix is important in providing all but;***

(a) tensile strength (b) hardness
(c) to resist stretch (d) flexibility

(iii) ***The remodeling of bone is a function of which cells?***

(a) chondrocytes and osteocytes (b) osteoblasts and osteoclasts
(c) chondroblasts and osteoclasts (d) osteoblasts and osteocytes

(iv) ***In skeletal muscle, calcium facilitates contraction by binding to***

(a) tropomyosin (b) actin.
(c) troponin. (d) myosin.

(v) ***Which of the following statements concerning the role of*** Ca^{+2} ***in the contraction of skeletal muscle is correct?***

(a) The mitochondria act as a store of Ca^{++} for the contractile process
(b) Ca^{+2} entry across the plasma membrane is important in sustaining the contraction of skeletal muscle
c) A rise in intracellular Ca^{+2}allows actin to interact with myosin
d) The tension of a skeletal muscle fibre is partly regulated by G proteins
muscle

(vi) ***The function of the T tubules in muscle contraction is to***

(a) make and store glycogen
(b) release Ca^{+2} into the cell interior and then pick it up again
(c) make the action potential deep into the muscle cells
(d) to hamper the the nerve impulse

(vii) ***The sites where the motor nerve impulse is transmitted from the nerve endings to the skeletal muscle cell membranes are the:***

(a) neuromuscular junctions (b) sarcomeres
(c) myofilaments (d) Z discs

MDCAT BY FUTURE DOCTORS (TOUSEEF AHMAD)

EXERCISE

(viii) Myoglobin has a special function in muscle tissue.

(a) it breaks down glycogen
(b) it is a contractile protein
(c) it holds a reserve supply of oxygen in the muscle
(d) none of these

2- **Short Questions**

(i) Name the cranial and facial bones
(ii) What is the function of the intervertebral discs?

(iv) Briefly describe the impairment of function seen in cleft palate.

3- **Long Questions**

(i) Describe the structure of bone.
(ii) Describe major divisions of human axial skeleton
(iii) What are types of fractures? Describe the repair process of a simple fracture.
(iv) Compare smooth, cardiac, and skeletal muscles.
(v) Explain the ultra-structure of human skeletal muscles.
(vi) Explain the sliding filament theory of contraction using appropriately labeled diagrams of a relaxed and a contracted sarcomere.
(vii) Describe the structure of a sarcomere and indicate the relationship of the sarcomere to the myofilament

Analyzing and Interpreting

- Identify the bones of the pelvic girdle, pectoral girdle, arms and leg by using the model of human skeleton.
- Compare the structure of skeleton, smooth and cardiac muscles with the help of prepared slides.
- Draw a diagram of sarcomere and label its parts.
- Justify how the main functions of the skeleton are to act as a system of rods and levers, which are moved by the muscles.
- Justify why do the muscles pull but do not push.

MDCAT BY FUTURE DOCTORS (TOUSEEF AHMAD)

EXERCISE

Initiating and Planning

- Relate the bipedal posture of man with his skeleton and musculature.

Science, Technology, and Society Connections

- Name the techniques for joint transplantation.
- Justify the use of calcium in teenage and twenties can be a preventive action against osteoporosis.
- Reason out the rigor mortis.
- Relate improper posture to bone/joint problems.

Online Learning

- www.muscleandfitness.com
- www.muscleandstrength.com
- www.getbodysmart.com/ap/muscles/musclesystem
- muscle.ucsd.edu
- www.innerbody.com